

## Case Report

# Simultaneous Application of Combination of Three Surgical Techniques for Treatment of Gingival Recession: A Case Report

**Tatiana Miranda Deliberador, Felipe Rychuv Santos, Alvaro Francisco Bosco\*, Flávia Aparecida Chaves Furlaneto\*, Michel Reis Messoria\*\*, Allan Fernando Giovanini and Maria José Hitomi Nagata\***

*Master Program in Clinical Dentistry, Positivo University (UP), Curitiba, PR, Brazil*

*\* Department of Surgery and Integrated Clinic, Division of Periodontics, São Paulo State University (UNESP), Araçatuba, SP, Brasil*

*\*\* Division of Integrated Clinic, Dental School of Lavras, Lavras University Center (UNILAVRAS), Lavras, MG, Brazil*

Received 3 March, 2010/Accepted for publication 14 June, 2010

## Abstract

The treatment of Miller class III gingival recession is considered a challenge in periodontal practice, and among the different techniques used, autogenous connective tissue graft has shown the most favorable results. In some cases, more than one procedure may be necessary. In this case report, we describe the simultaneous application of a combination of three techniques (the tunnel technique, a connective tissue graft and a laterally positioned flap) to treat a Miller class III gingival recession localized in the lower anterior region. Twelve months after surgical procedures, partial root coverage, favorable esthetic results and a gain in clinical attachment level were observed, with no periodontal pockets or bleeding on probing.

**Key words:** Gingival recession—Root coverage—Connective tissue graft—Periodontal plastic surgery—Esthetics

## Case

A 46-year-old African American woman came to the dental clinic of the School of Dentistry of Araçatuba, São Paulo State University (UNESP), for treatment. Her chief complaint was the lack of esthetics in the lower anterior

region and root sensitivity that had persisted for 3.5 years. Her anamnesis revealed no systemic health problems or deleterious oral habits. After clinical examination, with a diagnosis of mild localized chronic periodontitis was reached. Miller class III recession and lack of attached tissue on Tooth #31 (the lower left

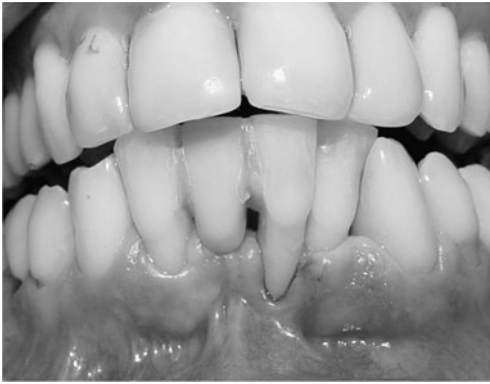

Fig. 1 At baseline, clinical examination revealed Miller class III recession and lack of attached tissue on Tooth #31 (lower left central incisor) and Miller class II recession on Tooth #42 (lower right lateral incisor)

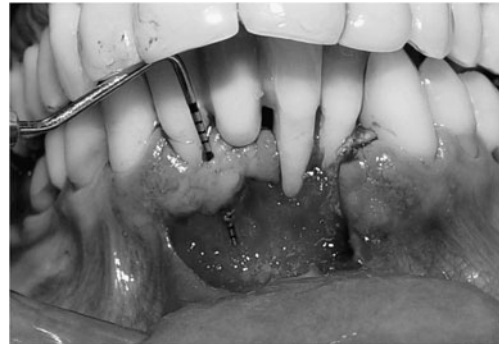

Fig. 2 Partial thickness dissection

central incisor) and Miller class II recession on Tooth #42 (the lower right lateral incisor) were also observed (Fig. 1). A probing depth of 1 mm was found for Tooth #31 with bleeding on probing, 7 mm gingival recession and an 8 mm clinical attachment level. A probing depth of 1 mm was found for Tooth #42, with bleeding on probing, 5 mm gingival recession and a 5 mm clinical attachment level. The possible etiology was considered to be incorrect tooth-brushing technique in combination with abnormal frenum attachment.

Based on the particular clinical conditions, this was considered to be a complex case. Therefore, a combination of three different techniques was used (the tunnel technique, a subepithelial connective tissue graft (SCTG) and a laterally positioned flap), since the use of a single technique would have been insufficient to obtain both good aesthetics and gingival recuperation.

The patient authorized the treatment to be performed, the use of images taken during treatment and follow-up appointments. Initially, the patient received periodontal treatment, including oral hygiene instructions and scaling and root planing. Four weeks later at her re-evaluation, good plaque control and no signs of active inflammation were observed. The combination of tunnel technique, SCTG and laterally positioned flap

was performed on the recession defects one week later. After proper patient preparation and local anesthesia, a sulcular incision was made from Tooth #31 (the lower left lateral incisor) to Tooth #42. In addition, an incision was made on the mucogingival junction from the distal region corresponding to Tooth #31 to the distal region corresponding to the Tooth #42. Two incisions on distal #42 and mesial #31 were made perpendicularly to the mucogingival incision. Incisions were also planned and carried out to remove abnormal frenum attachment. A partial thickness flap was then elevated. Subsequently, at the region corresponding to #42, a subepithelial dissection for the tunnel technique was performed from the sulcus to the horizontal incision at the mucogingival junction (Fig. 2). The root surfaces were then scaled, planed and decontaminated with tetracycline hydrochloride (a 500 mg capsule diluted in 5 ml saline).

An autogenous connective tissue graft from the palate was harvested using a previously described technique<sup>6</sup>. For the tunnel technique, the graft was gently placed under the flap and sutured with 5-0 vycril (Fig. 3). Next, a laterally positioned flap was placed over the connective tissue graft in order to cover it partially, after which it was sutured appropriately with 5-0 vycril and 4-0 silk (Fig. 4). The surgical sites were then covered with periodontal dressing.

After completion of surgical procedures, the patient received pain control medication (an acetaminophen-containing analgesic) when

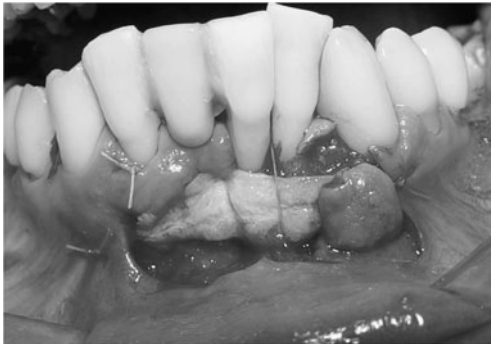


Fig. 3 Autogenous connective tissue graft sutured at recipient site

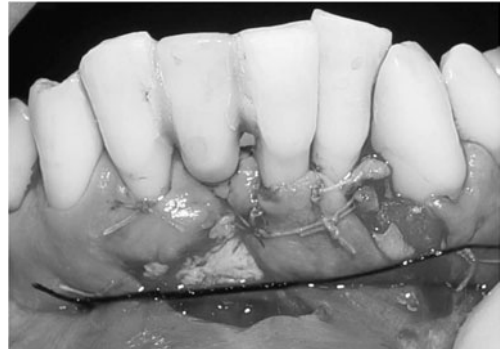

Fig. 4 Graft and lateral flap sutured

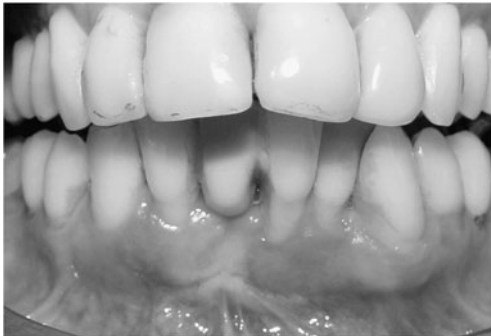

Fig. 5 Periodontal and esthetic conditions at 3-month postoperative follow-up

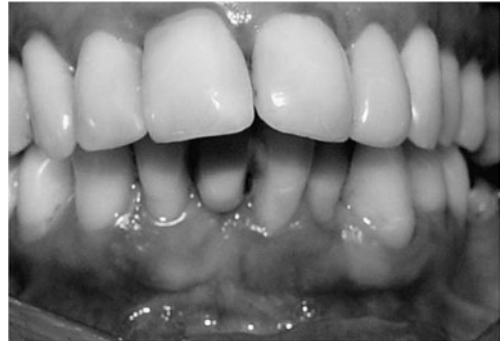

Fig. 6 Partial root coverage and favorable esthetic results observed at 12-month postoperative follow-up

Table 1 Pre and postoperative clinical parameters

	Tooth #31		Tooth #42	
	Preoperative	Postoperative	Preoperative	Postoperative
Probing depth	1 mm	0.5 mm	1 mm	0.5 mm
Bleeding on probing	Yes	No	Yes	No
Gingival recession	7 mm	3 mm	5 mm	1.5 mm
Clinical attachment level	8 mm	3.5 mm	5 mm	2 mm

needed, an antibiotic (500 mg amoxicillin, 3 times a day for 7 days) and chemical plaque control (0.12% chlorhexidine gluconate rinse, 2 times a day for 14 days). The sutures and dressing were removed after 7 days, and follow-up visits were scheduled for 20, 40, 90 and 365 days. Three months later, the patient reported that she was completely satisfied with the esthetic outcome (Fig. 5). One year after the surgical procedures, partial root

coverage and favorable esthetic results were observed, with no periodontal pockets or bleeding on probing. A probing depth of 0.5 mm was found in Tooth #31, with 3 mm gingival recession and a 3.5 mm clinical attachment level. A probing depth of 0.5 mm was found in Tooth #42, with 1.5 mm gingival recession and a 2 mm clinical attachment level (Fig. 6). The gain in clinical attachment level was 4.5 mm and 3 mm for Tooth #31 and #42,

respectively (Table 1). Additional root coverage occurred between 6 and 12 months as a result of creeping attachment.

## Discussion

Gingival recession seems to be the most common esthetic complaint reported by periodontal patients<sup>2)</sup>. According to the Glossary of periodontal terms, published by the American Academy of Periodontology, gingival recession is defined as the displacement of the soft tissue margin, apical to the cemento-enamel junction, and its coverage is one of the most challenging procedures in periodontics. Recession can affect one or more teeth. Furthermore, it can be associated with root sensibility and smile disharmony<sup>9)</sup>. Several different factors have been proposed in the etiology of gingival recession, including periodontal disease, faulty tooth-brushing<sup>3)</sup>, tooth malpositioning, aging, trauma from occlusion, abnormal frenum attachment and lack of keratinized tissue<sup>18)</sup>.

Several different techniques for root coverage have been proposed. Over the years, techniques with more predictable results have been developed to treat gingival recession such as the SCTG. This technique was first described by Langer and Langer<sup>15)</sup>. An SCTG is usually harvested from the palate and placed over the recession and under a mucoperiosteal flap. The SCTG technique offers excellent esthetic result, as well as a very predictable percentage of root coverage, when properly indicated<sup>1,7,8,13,14,20)</sup>.

In many cases, more than one procedure is necessary to treat gingival recession. Consequently, the combination of two or more procedures has been increasingly used to provide successful results<sup>5,19,21)</sup>. According to the literature, many factors influence the level of success of each procedure, among which interproximal bone level and selection of the most adequate technique for a particular case are the most important<sup>11)</sup>. Currently, SCTG in combination with a coronally advanced flap is the technique for treating gingival recessions

with the most predictable results<sup>14)</sup>. However, other procedures can also provide an adequate level of clinical success, when well indicated.

In this case report, the patient had a complex recession defect due to the lack of keratinized tissue and loss of interproximal attachment level. A combination of techniques (tunnel technique, SCTG, and laterally positioned flap) was determined to be the best treatment. The objective of the surgery was to increase the amount of attached tissue and obtain adequate recession coverage. The utilization of a laterally positioned flap was employed to increase the amount of attached tissue on Tooth #31 from Tooth #32. Concomitantly, the SCTG was also employed for this objective as previously described in the literature<sup>1,13-15)</sup>. The tunnel technique was carried out to ensure the preservation of the interproximal papilla<sup>1)</sup> and facilitate fixation of the graft for root coverage. The tunnel technique also provides minimal post-operative complications and good esthetic results.

The one-year follow-up visit demonstrated only partial recession coverage. The recession coverage demonstrated in this case is in accordance with previous literature<sup>12)</sup>, where only partial recession coverage was achieved in Miller class III defects, regardless of the technique performed<sup>22)</sup>. In the present case, creeping attachment was also observed during the first year of healing. Creeping attachment was first described by Goldman and Cohen<sup>10)</sup> and is defined as partial coronal migration of the flap during healing. Creeping attachment has been shown to be more prominent in the anterior region in narrow recession defects<sup>4,16,17)</sup>. Matter<sup>16)</sup> has demonstrated an average of 1 mm creeping attachment 12 months postoperatively.

The combination of different surgical techniques contributed to the success, both clinical and esthetic, in the treatment of gingival recession. We have described a case in which class II and III gingival recession was treated utilizing a combination of three different approaches. The surgical procedure yielded favorable esthetic outcomes and complete patient satisfaction. Further randomized

clinical trials with a larger population must be conducted to further evaluate the success of the technique employed.

### References

- 1) Allen AL (1994) Use of the supraperiosteal envelope in soft tissue grafting for root coverage. I. Rationale and technique. *Int J Periodontics Restorative Dent* 14:216–227.
- 2) Allen AL (1994) Use of the supraperiosteal envelope in soft tissue grafting for root coverage. II. Clinical results. *Int J Periodontics Restorative Dent* 14:302–315.
- 3) Baker DL, Seymour GJ (1976) The possible pathogenesis of gingival recession. *J Clin Periodontol* 3:208–219.
- 4) Bell LA, Valluzzo TA, Garnick JJ, Pennel BM (1978) The presence of creeping attachment in human gingival. *J Periodontol* 49:513–517.
- 5) Borghetti A, Louise F (1994) Controlled clinical evaluation of the subpedicle connective tissue graft for the coverage of gingival recession. *J Periodontol* 65:1707–1712.
- 6) Bosco AF, Bosco JMD (2007) An alternative technique to the harvesting of a connective tissue graft from a thin palate. Enhanced wound healing. *Int J Periodontics Restorative Dent* 27:133–139.
- 7) Bouchard P, Nilveus R, Etienne D (1997) Clinical evaluation of tetracycline HCl conditioning in the treatment of gingival recessions. A comparative study. *J Periodontol* 68:262–269.
- 8) Caffesse RG, De Larosa M, Garza M, Munne-Travers A, Mondragon JC, Weltman R (2000) Citric acid demineralization and subepithelial connective tissue grafts. *J Periodontol* 71:568–572.
- 9) De Waal H, Kons S, Ruben MP (1988) The laterally positioned flap. *Dent Clin North Am* 32:267–285.
- 10) Goldman HM, Cohen DW (1973) *Periodontal therapy*, 5th ed., pp.751–758, Mosby, Philadelphia.
- 11) Greenwell H, Bissada NF, Henderson RD, Dodge RJ (2000) The deceptive nature of root coverage results. *J Periodontol* 71:1327–1337.
- 12) Guinard EA, Caffesse RG (1978) Treatment of localized gingival recessions. Part III. Comparison of results obtained with lateral sliding and coronally repositioned flaps. *J Periodontol* 49:457–461.
- 13) Harris RJ (1992) The connective tissue and partial thickness double pedicle graft: a predictable method of obtaining root coverage. *J Periodontol* 63:477–486.
- 14) Harris RJ, Harris AW (1994) The coronally positioned pedicle graft with inlaid margins: a predictable method of obtaining root coverage of shallow defects. *Int J Periodontics Restorative Dent* 14:228–241.
- 15) Langer B, Langer L (1985) Subepithelial connective tissue graft technique for root coverage. *J Periodontol* 56:715–720.
- 16) Matter J (1980) Creeping attachment of free gingival grafts. A five year follow-up study. *J Periodontol* 51:681–685.
- 17) Matter J, Cimasoni G (1976) Creeping attachment after free gingival grafts. *J Periodontol* 47:574–579.
- 18) Miller PD (1985) A classification of marginal tissue recession. *Int J Periodontics Restorative Dent* 5:8–13.
- 19) Nelson SW (1987) The subpedicle connective tissue graft: a bilaminar reconstructive procedure for the coverage of denuded root surfaces. *J Periodontol* 58:95–102.
- 20) Paolantonio M (2002) Treatment of gingival recessions by combined periodontal regenerative technique, guided tissue regeneration, and subpedicle connective tissue graft. A comparative clinical study. *J Periodontol* 73:53–62.
- 21) Zabalegui I (1999) Treatment of multiple adjacent gingival recessions with the tunnel subepithelial connective tissue graft: a clinical report. *Int J Periodontics Restorative Dent* 19:199–206.
- 22) Zucchelli G, Cesari C, Amore C, Montebugnoli L, De Sanctis M (2004) Laterally moved, coronally advanced flap: a modified surgical approach for isolated recession-type defects. *J Periodontol* 75:1734–1741.

#### *Reprint requests to:*

Dr. Tatiana Miranda Deliberador  
Mestrado em Odontologia,  
Universidade Positivo,  
Rua Prof. Pedro Viriato Parigot  
de Souza, 5300  
CEP 81280-330, Campo Comprido,  
Curitiba, PR, Brazil  
E-mail: tdeliberador@up.edu.br/  
tdeliberador@gmail.com