

Case Report Article

Treatment of peri-implantitis with particulate bone graft in a smoker patient

Marina Samara Baechtold¹
Aline Rocha Miquelissa¹
Viviane Rozeira Crivellaro¹
Rafaela Scariot¹
João César Zielak¹
Tatiana Miranda Deliberador¹

Corresponding author:

Tatiana Miranda Deliberador
Rua Eduardo Sprada, n. 3439, casa 10 – Campo Comprido
CEP 81210-370 – Curitiba – PR – Brasil
E-mail: tdeliberador@up.edu.br

¹ Dentistry Course, Positivo University – Curitiba – PR – Brazil.

Received for publication: October 14, 2017. Accepted for publication: December 5, 2017.

Keywords:

peri-implantitis; bone transplantation; bone regeneration.

Abstract

Introduction: With the increase of implant-supported rehabilitation, the cases of patients with peri-implantitis become more frequent. **Objective:** To report the treatment of peri-implantitis by associating techniques of bone surface decontamination and particulate graft. **Case report:** The treatment was carried through curettage of the granulation tissue, mechanical bone decontamination with bicarbonate jet, chemical decontamination with tetracycline solution, and particulate graft in the place of the bone defect. **Conclusion:** After 45 postoperative days, the peri-implant tissues were health without inflammation. After 6 postoperative months, the bone defect was repaired.

Introduction

In the last few decades, the dental implants have been an excellent alternative for rehabilitation of partial or total edentulous patients. In addition to the functional comfort for speech and chew, the implants confer excellent aesthetic, which is very attractive for the patient. Although the high index of success, some implants may undergo peri-implantitis. The causes of peri-implantitis

vary and can occur due to the accumulation of plaque in the peri-implant tissue, history of periodontitis, systemic diseases (diabetes mellitus and osteoporosis), tobacco, and alcohol. Moreover, prosthesis with premature contact, badly located implant or that undergoing great load of badly adapted prosthesis also can lead to peri-implantitis. Overall, the occlusal overload and the peri-implantitis are the probable causes of the osseointegration loss [6].

Peri-implantitis is defined as an inflammatory process that affects the hard and soft tissue surrounding the osseointegrated implant, resulting in loss of bone support, associate with the increase of the probing depth higher than 5 mm with presence of bleed to probing, with probable light pain, mobility, and suppuration. Moreover, the bone defect radiographically has crater-shape appearance [1].

The non-surgical treatment of peri-implantitis involves the curettage, alternative therapies, as laser therapy, photodynamic therapy, and use of jet with abrasive substance in the affected region. However, the use of non-surgical treatments results most of the time in limited clinical results. In case of clear bone loss and probing depth higher than 5 mm, the surgical treatment with surface decontamination associated or not with the bone graft is the treatment of choice [8].

This case report aimed to describe the peri-implantitis treatment by associating techniques of bone surface decontamination and particulate bone graft.

Case report

A male patient aged 55 years, searched for dental care in the Positive University with the main complaint of gingival edema and moderate pain in the implant at the region of tooth #46, carried through approximately 7 years ago. Throughout anamnesis, the patient reported no systemic diseases, a treated periodontal disease, but she was treated, and to be a smoker. The radiographic examination evidenced crater-shaped bone loss in periapical radiograph, an injury characteristic of peri-implantitis in the implant at the region of tooth #46 (figure 1).

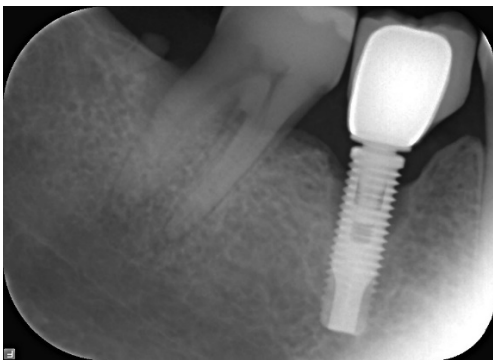


Figure 1 - Periapical radiographic image of the region of the implant of tooth #46 showing crater-shape bone defect

At the clinical examination, the periodontal probing was carried through, presenting 10 mm

of probing depth (figure 2). It was not possible to remove the fixed prosthesis (figure 3). The patient was diagnosed with peri-implantitis.

The treatment plan comprised surgical intervention with curettage and mechanical decontamination with bicarbonate jet, chemical decontamination with tetracycline, and particulate bone graft.

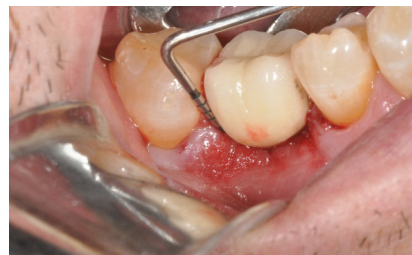

Figure 2 - Clinical image of the peri-implantitis probing measuring 10 mm

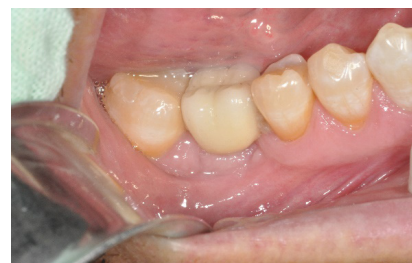

Figure 3 - Initial clinical image of implant at the area of tooth #46 with cemented crown

Previously to the beginning of the surgery, mouth antiseptics was performed with 0.12% chlorhexidine digluconate. The regional block of the inferior alveolar nerve was performed with Articaine solution 4% with 1:100.000 adrenalin (Articaine® - DFL Industry and Commerce Ltda., Rio De Janeiro, Brazil). After that, with the aid of scalpel blade #15, an intrasulcular incision was executed on teeth #45 and #47 (figure 4). Next, the total a buccal and lingual flap was raised to access the tissue granulated that was next to the implant (figure 5).

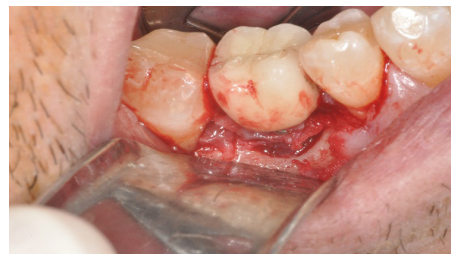

Figure 4 - Clinical image after intrasulcular incision and raising of total thickness flap. It is observed the presence of granulation tissue at the buccal surface of the dental implant

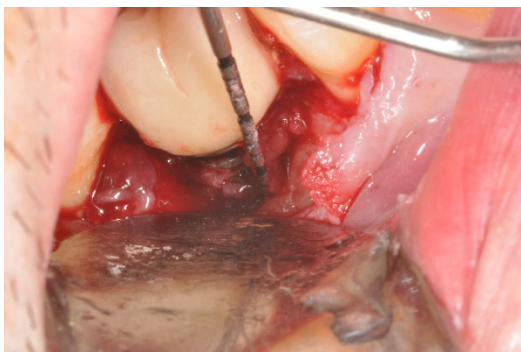

Figure 5 - Clinical image of the peri-implantitis and probing after flap raising.

Curettage of the granulation tissue was performed with Gracey curette #7/8, associated with the bicarbonate jet and use of tetracycline. A capsule of 500 mg was dissolved in 5 ml of serum, and the suspended solution was rubbed in the surface of the implant following irrigation with saline solution (figure 6).

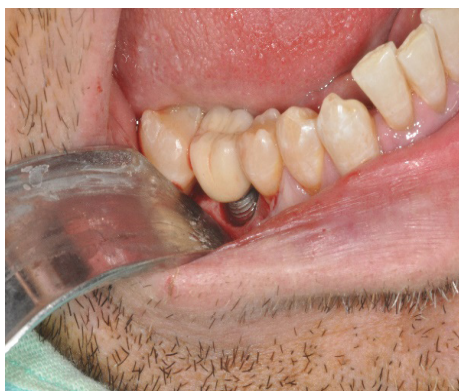

Figure 6 - Post-treatment clinical image, removal of the granulation tissue, bicarbonate jet, and tetracycline conditioning

After the mechanical and chemical decontamination, the bone defect was filled with particulate bovine bone graft Lumina Bone® (Criteria - bone of bovine origin, average granules: 425 to 600 μ - 0.6cm³). The tissues were repositioned and sutured with simple sutures with silk thread 4.0. At the end of the surgery, a periapical radiograph was taken for following-up (figure 7).

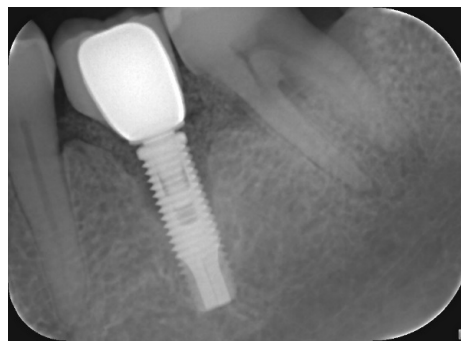


Figure 7 - Immediate periapical image. Note the defect filled with bovine graft

The prescribed postoperative medication consisted of Amoxicillin 500 mg - 1 capsule, oral route, at every 8 hours, for 7 days; Metronidazole 400 mg - 1 tablet, oral route at every 8 hours, for 14 days; Ibuprofen 600 mg - 1 tablet, oral route at every 8 hours, for 5 days; 0.12% chlorhexidine digluconate - mouth washing at every 12 hours, for 14 days.

The suture was removed 10 days after the surgery. At 45 postoperative days, the patient did not present any clinical signals of peri-implantitis inflammation. At 6 postoperative months, the patient returned for following-up. The clinical examination revealed no of increased probing depth and bleed to probing. The radiographic examination revealed that the bone defect was partially filled by new bone (figure 8).

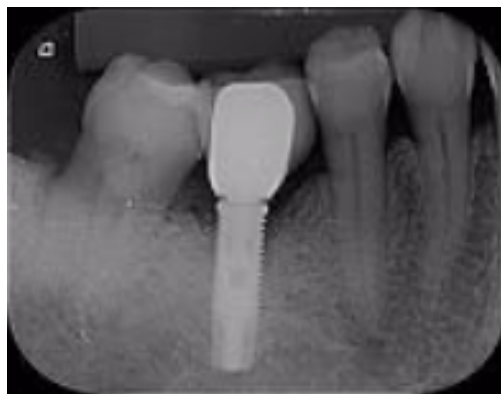

Figure 8 - Periapical radiographic image 6 months after the treatment, with reduction of the peri-implantitis bone defect

Discussion

The oral hygiene instruction, mechanical and chemical surface decontamination, use of antiseptics and antimicrobials (local and systemic), following-up and maintenance appointments are important adjuvant for the treatment of peri-implantitis, but they must be complemented with surgical treatment, to achieve bone regeneration and to prevent the loss of the implant over time [2]. Current evidences shown that the non-surgical therapy for peri-implantitis is minimally effective [8]. The dentist must be aware that peri-implantitis is of difficult treatment and unpredictable prognosis [5].

Among the predisposing factors of the peri-implantitis, tobacco is probably the most recurrent factor causing failure of dental implants [3, 6, 7]. Smokers had a correlation with significant marginal bone loss around of implants [4]. Similarly to which was observed in this case report.

The peri-implantitis incidence is considerably higher in smokers. However, smoking is not an absolute contraindication for the installation of implants, because the presence of an isolated risk factor is generally insufficient to cause failure [3, 6].

The access surgeries combined with decontamination of implant surface together with bone graft, and systemic antibiotic use revealed more efficient in the peri-implantitis treatment [1, 2, 5]. No method of decontamination of surface by itself (chemical agents, abrasive air jet, and lasers) is better than each other. This corroborates with the results of this case report, in which the treatment success of the peri-implantitis was accomplished by surgical treatment, bone surface decontamination, and graft.

Conclusion

The treatment carried through mechanical surgical debridement with curettes, bicarbonate jet, chemical decontamination associated with postoperative systemic medication, and particulate graft in the place of the peri-implantitis bone

defect together with daily oral hygiene can be a viable alternative for peri-implantitis treatment. This occurs even in smokers who are more prone to this disease.

References

1. Coli P, Christiaens V, Sennerby L, Bruyn H. Reliability of periodontal diagnostic tools for monitoring peri-implant health and disease. *Periodontol* 2000. 2017 Feb;73(1):203-17.
2. Francio L, Sousa AM, Storrer CLM, Deliberador TM, Sousa AC, Pizzato E et al. Periimplantitis treatment: literature review. *RSBO*. 2008;5(2):75-81.
3. Gürlek Ö, Gümüş P, Buduneli N. Smokers have a higher risk of inflammatory peri-implant disease than non-smokers. *Oral Dis*. 2017 Aug 11.
4. Klinge B, Hultin M, Berglundh T. Periimplantitis. *Dent Clin North Am*. 2005;49(3):661-76.
5. Lindhe J, Meyle J. Peri-implant diseases: consensus report of the Sixth European Workshop on Periodontology. *J Clin Periodontol*. 2008;35(8):282-5.
6. Marcantonio C, Nicoli LG, Marcantonio Junior E, Zandim-Barcelos DL. Prevalence and possible risk factors of peri-implantitis: a concept review. *J Contemp Dent Pract*. 2015 Sep 1;16(9):750-7.
7. McDermott NE, Chuang SK, Woo VV, Dodson TB. Complications of dental implants: identification, frequency and associated risk factors. *Int J Oral Maxillofac Implants*. 2003;18(6):848-855.
8. Suárez-López del Amo F, Faria e Almeida R, Cicciù M, Daugela P, Ramanauskaite A, Saulacic N, Tervonen T, Wang H, Yu S. The 1st Baltic Osseointegration Academy and Lithuanian University of Health Sciences Consensus Conference 2016. Summary and Consensus Statements: Group III – Peri-Implantitis Treatment. *J Oral Maxillofac Res*. 2016;7(3):e16.